

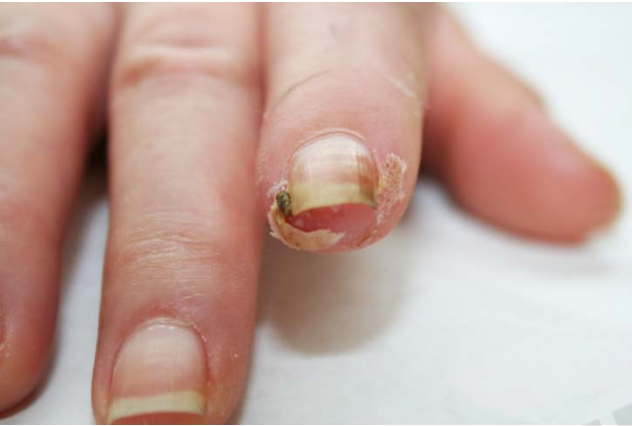# CASE #1

Patient#: 7810

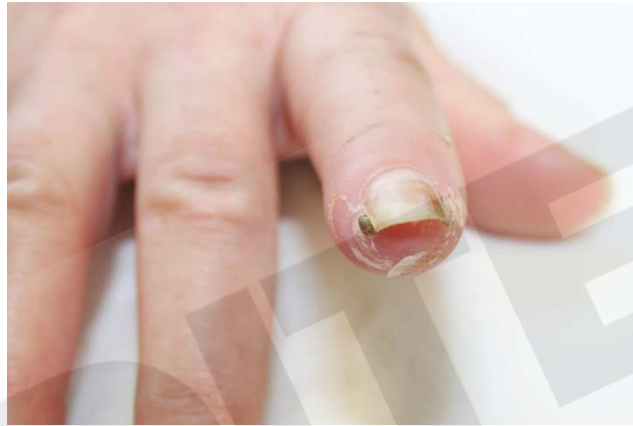Age: 51 F

Diagnosis: Reflex Sympathetic Dystrophy - Lesion

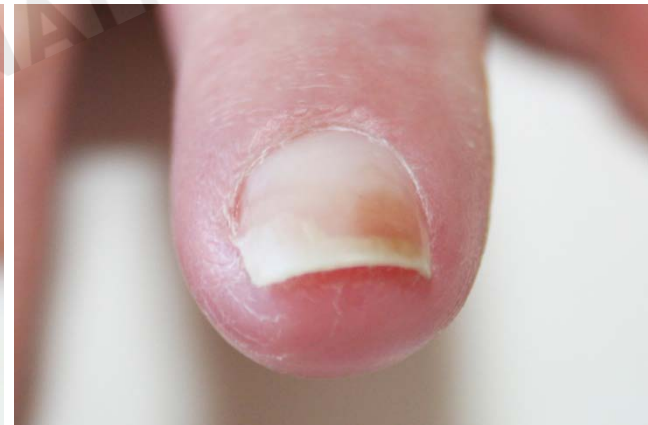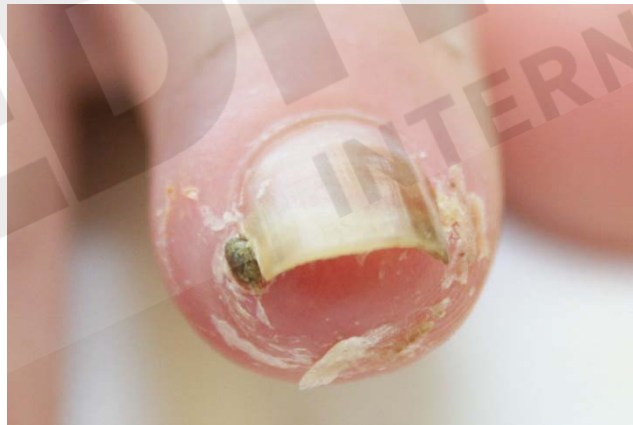
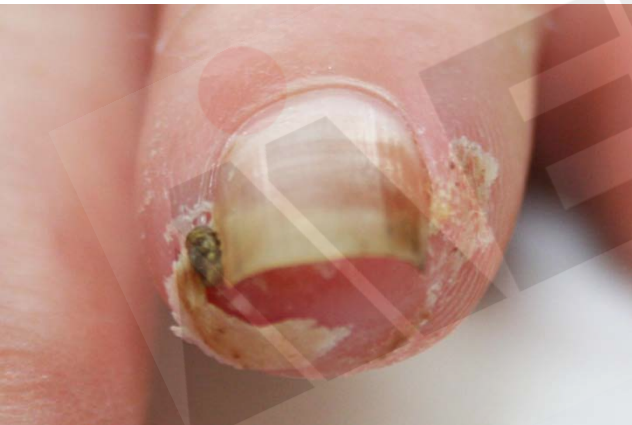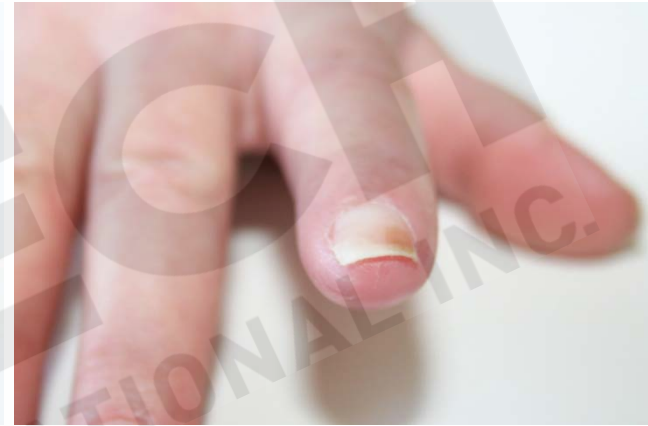**Initial**



**After 4 Treatments**



**After 10 Treatments**



**09/24/2010**

**10/04/2010**

**11/01/2010**

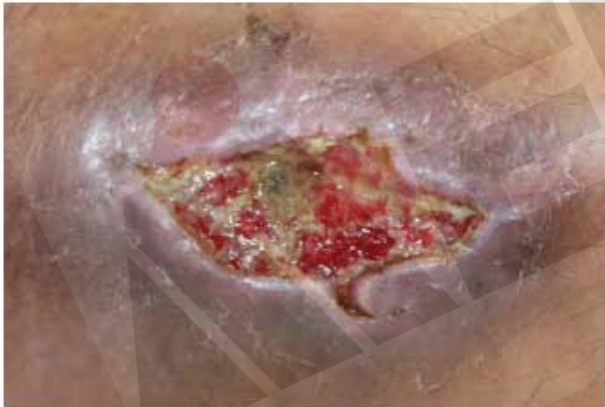
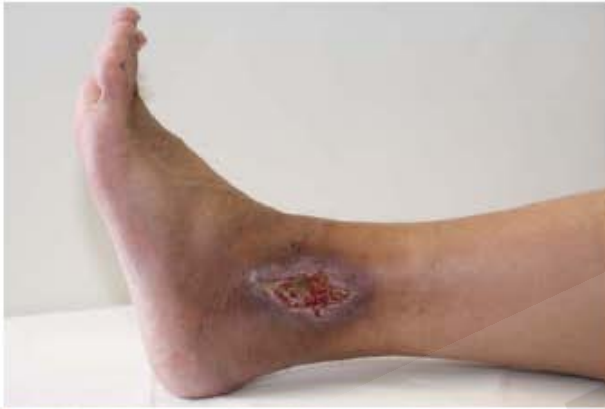# CASE #2

Patient#: 7108

Age: 32 M

Diagnosis: Chronic Wound (Osteomyelitis, Post-Surgery)

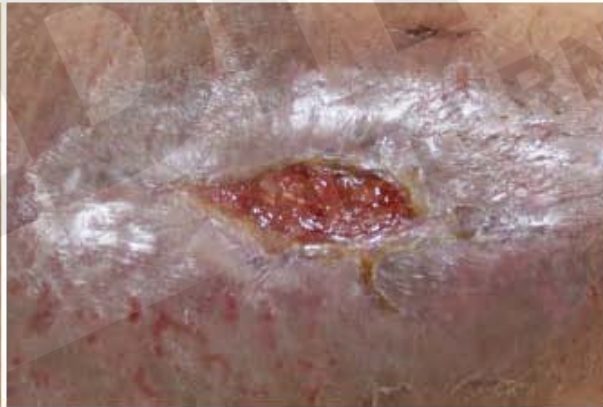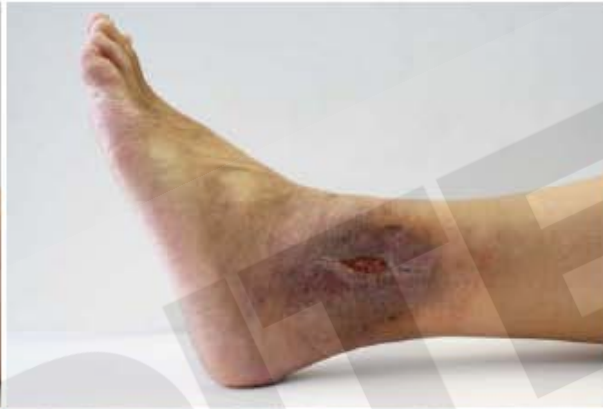After 4 Treatments



10/14/2009

Area: 8.47 cm<sup>2</sup>  
Perimeter: 14.41 cm

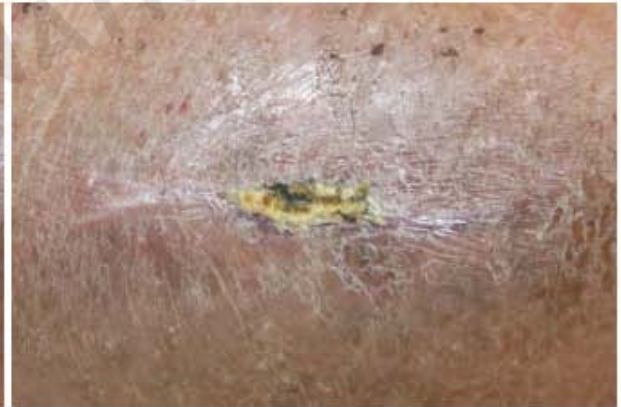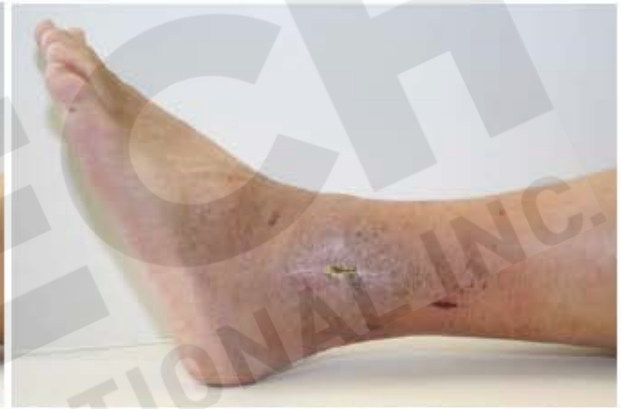Intermediate



11/16/2009

Area: 2.30 cm<sup>2</sup>  
Perimeter: 6.89 cm

Most Recent



12/30/2009

Area: 1.07 cm<sup>2</sup>  
Perimeter: 5.30 cm

Initial Measurement (10/09/2009)

Area: 9.36 cm<sup>2</sup>  
Perimeter: 17.51 cm

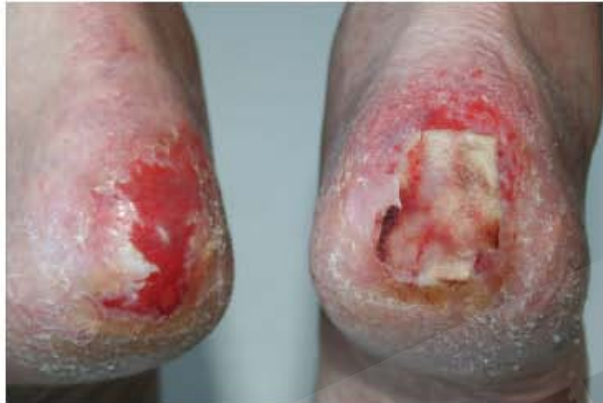# CASE #3

Patient#: 4783

Age: 90 M

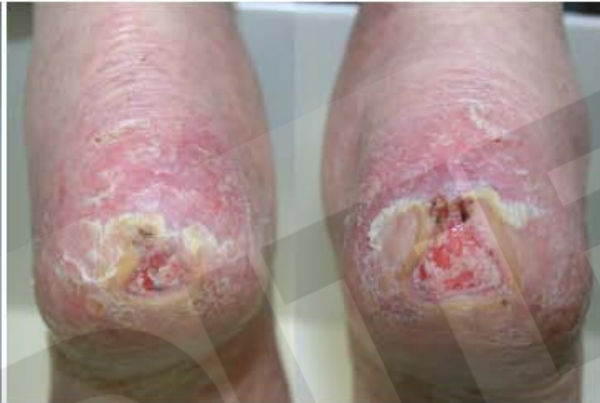Diagnosis: Dermal Ulcers; Hemochromatosis; Peripheral Arterial Occlusive Disease

Initial



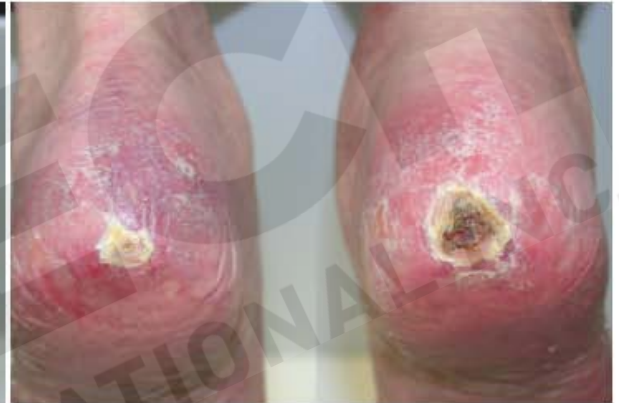11/03/2006

Intermediate I



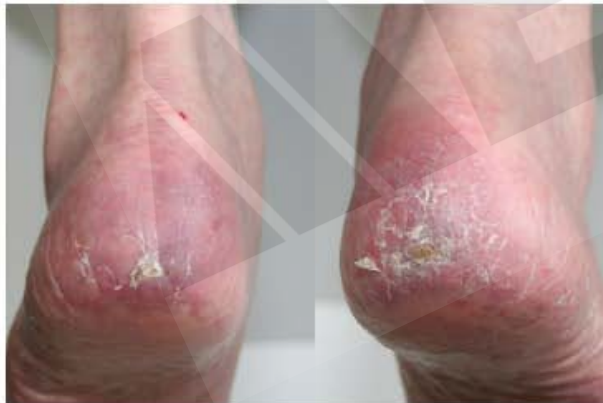12/02/2006

Intermediate II



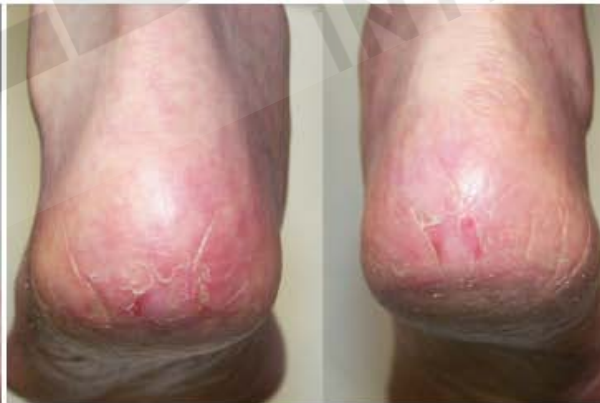01/04/2007

Final



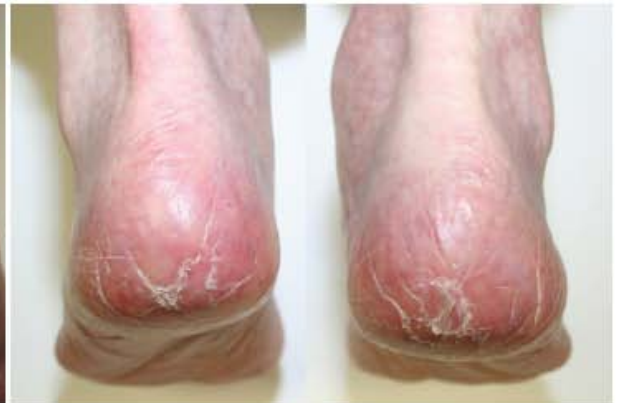01/26/2007

Follow-up 1 Year Post Treatment



12/03/2007

Most Recent



02/11/2009

# CASE #4

Patient#: 5244

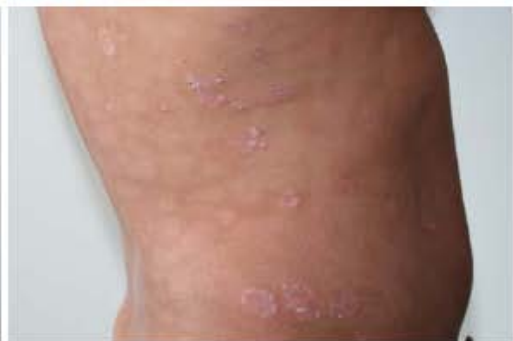
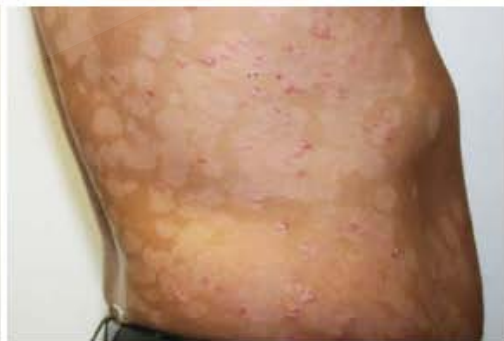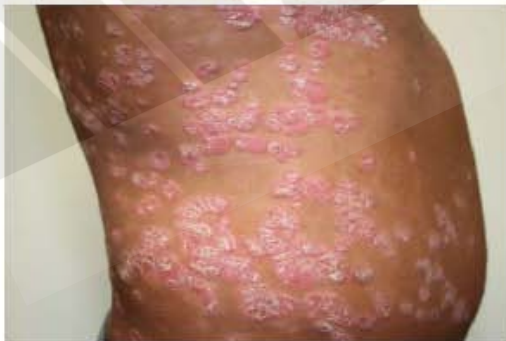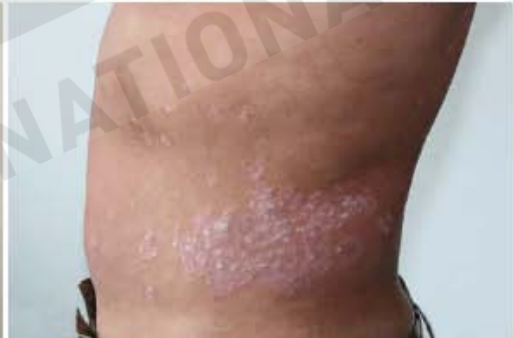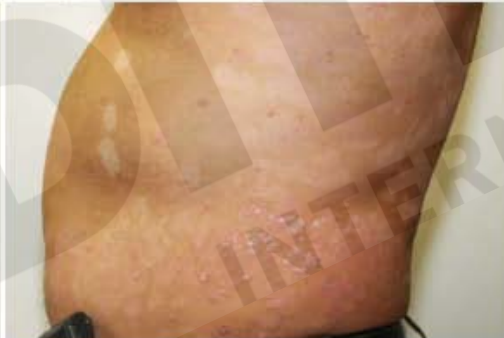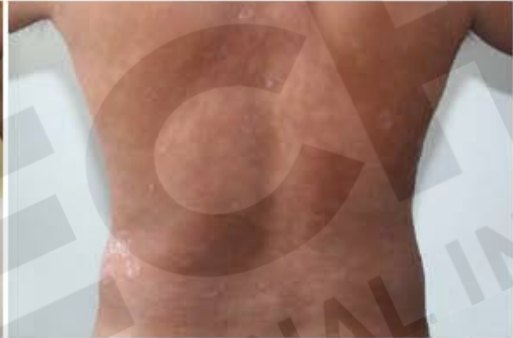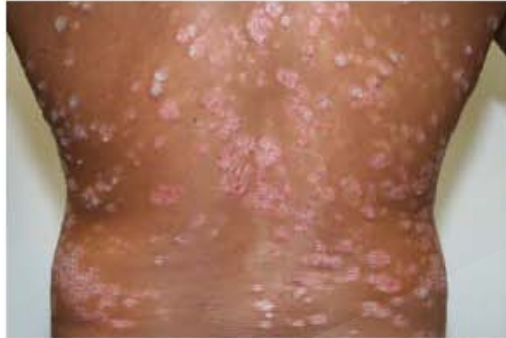Age: 54 M

Diagnosis: Psoriasis

Initial

Intermediate

Most Recent



06/05/2007

10/02/2007

04/25/2008

# CASE #5

Patient#: 5230

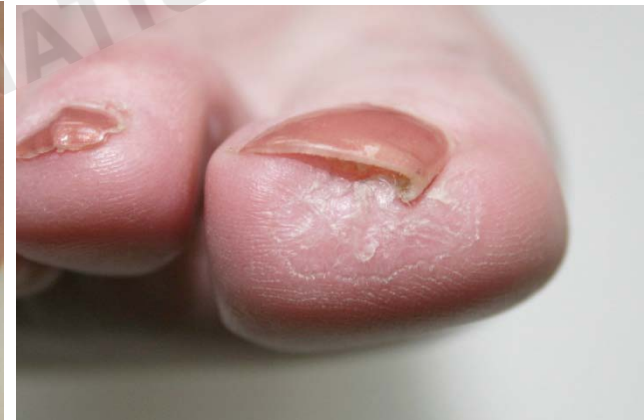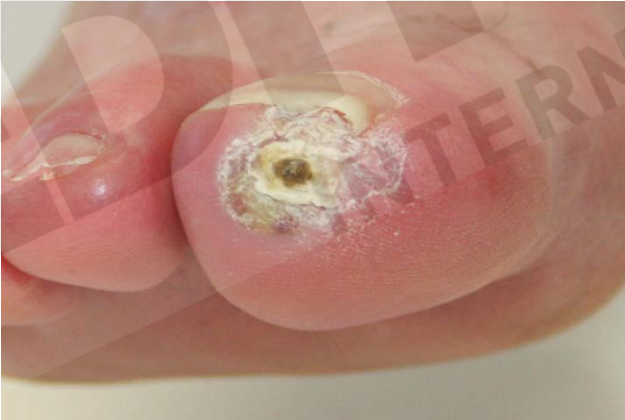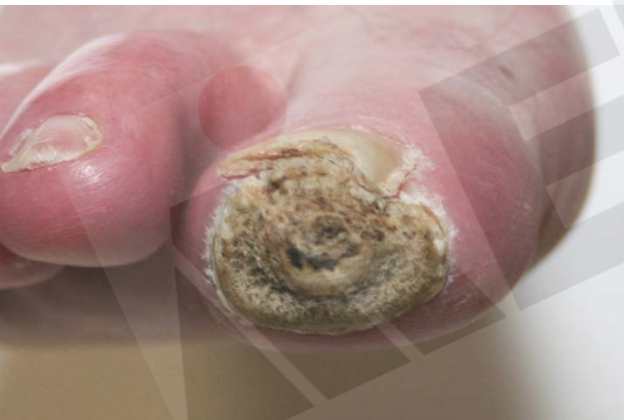
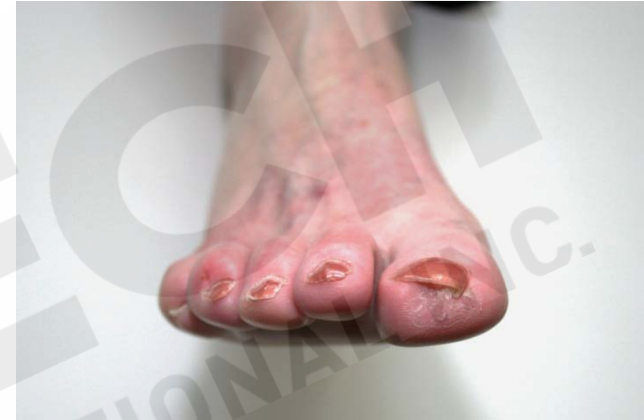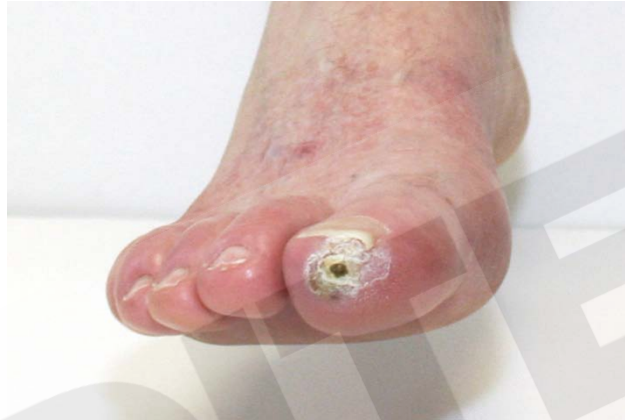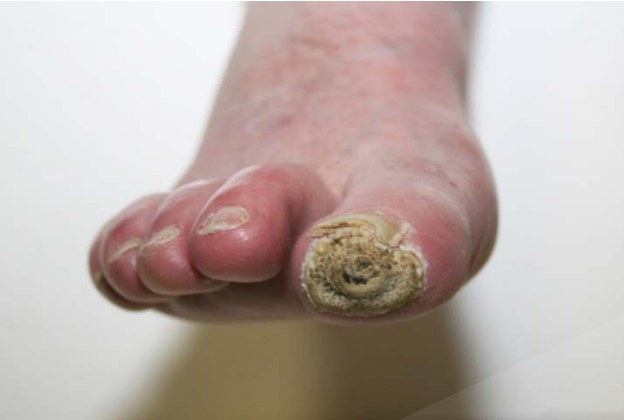Age: 50 F

Diagnosis: Pre-gangrenous foot – multiple ulcers secondary to Diabetes Mellitus

**Initial**

**Intermediate**

**Most Recent**



06/08/2007

04/01/2008

09/20/2008

# CASE #6

Patient#: 365

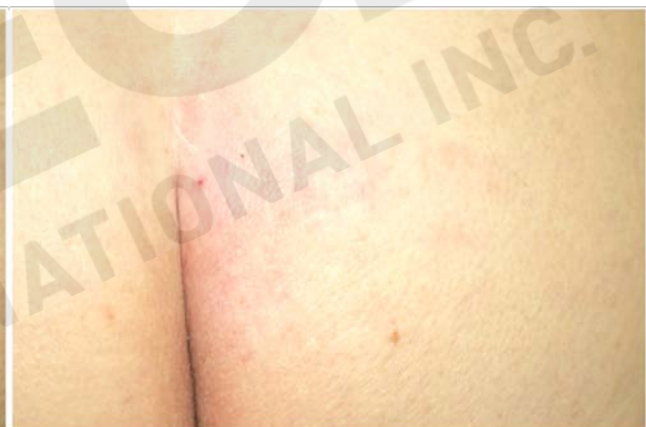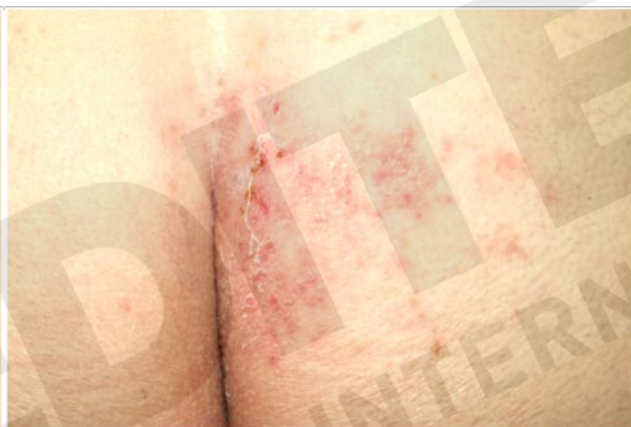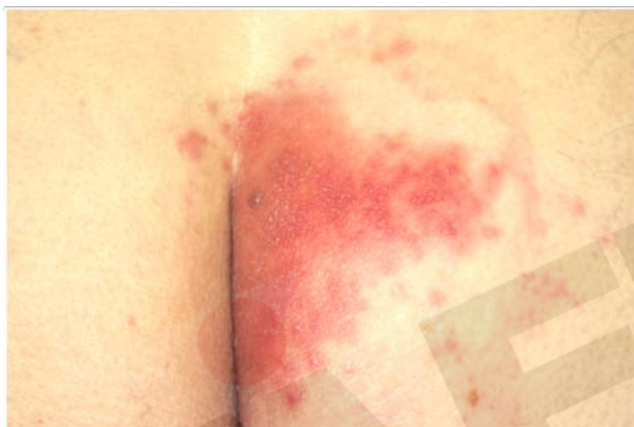Age: 77 M

Diagnosis: Herpes Zoster

**Initial**

**After 4 Treatments**

**After 6 Treatments**



**01/07/2011**

**01/12/2011**

**01/17/2011**

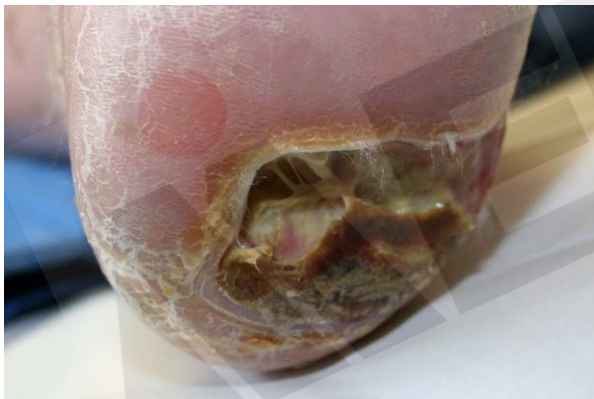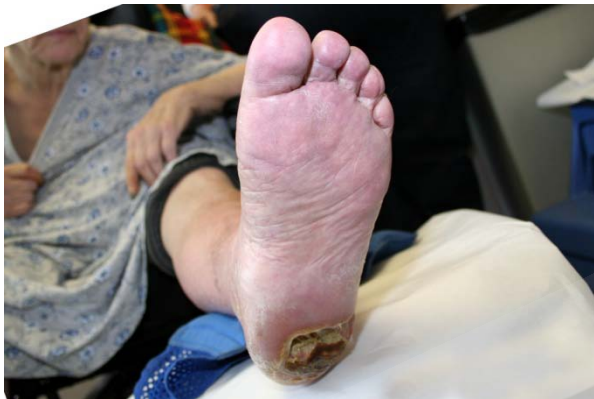# CASE #7

Patient##: 5364

Age: 62 F

Diagnosis: Infected Ulcer w/ impending Gangrene, left heel; IDDM

**Initial**

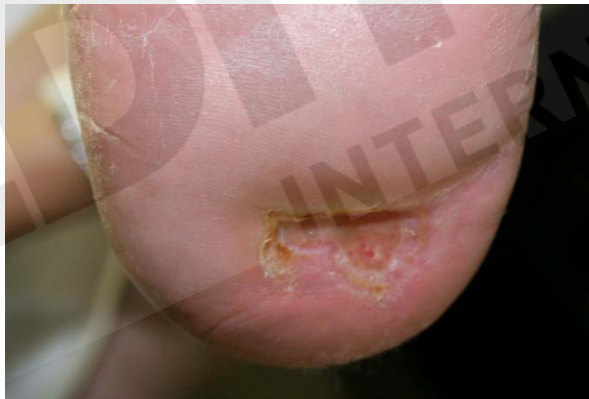
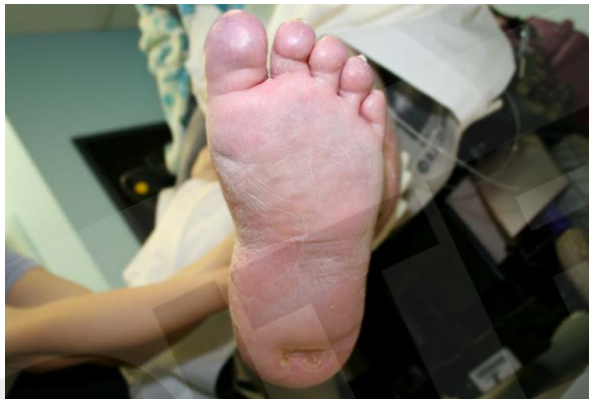
**07/11/2007**

## Measurement

Length: 5.45 cm  
Width: 2.85 cm  
Area: 9.23 cm<sup>2</sup>  
Perimeter: 13.57 cm

**Intermediate**

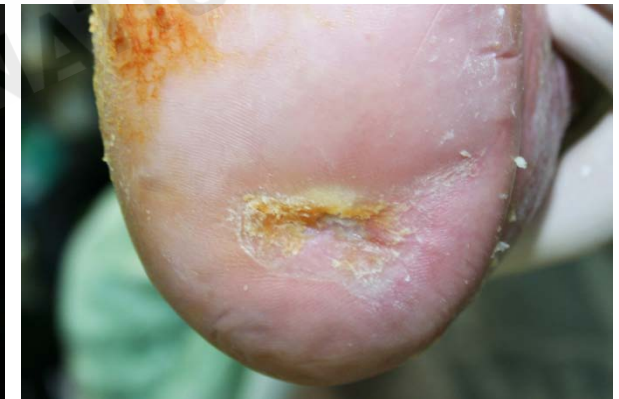
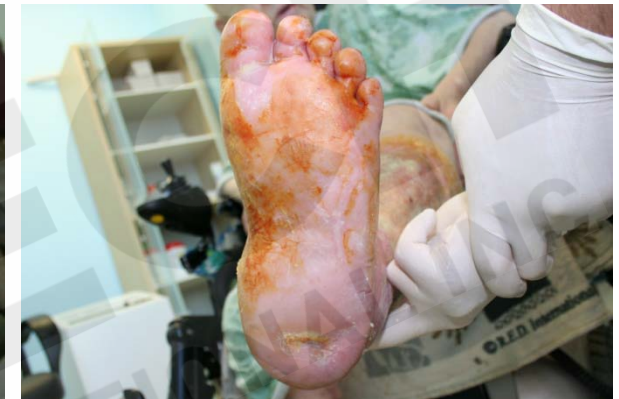
**10/09/2008**

## Measurement

Length: 2.09 cm  
Width: 1.12 cm  
Area: 1.48 cm<sup>2</sup>  
Perimeter: 5.71 cm

**Most Recent**



**06/15/2009**

## Measurement

Length: 1.45 cm  
Width: 0.43 cm  
Area: 0.53 cm<sup>2</sup>  
Perimeter: 3.39 cm

# CASE #8

Patient#: RC908

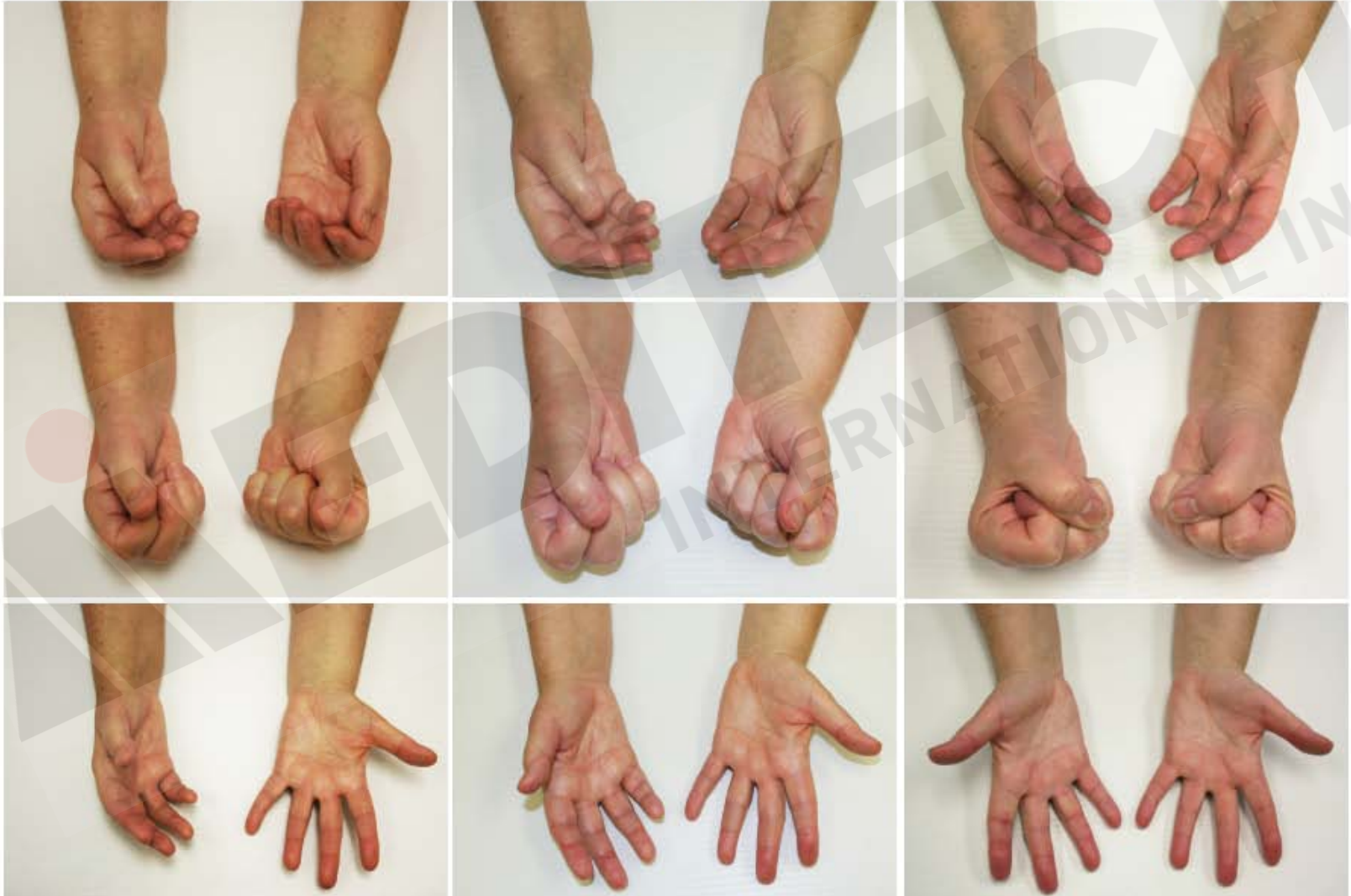Age: 60 F

Diagnosis: Reflex Sympathetic Dystrophy (Sudeck's Atrophy)

Initial

Intermediate

Most Recent



08/12/2009

08/14/2009

11/04/2009

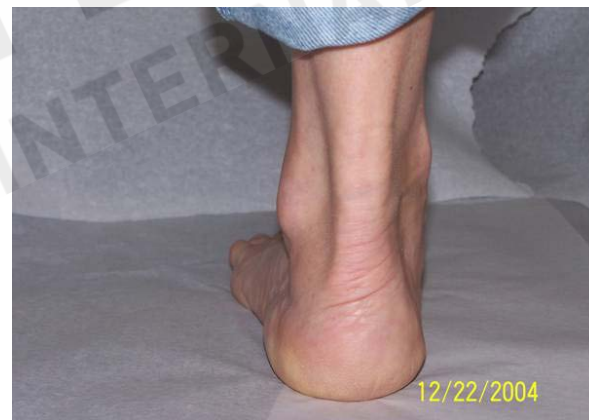
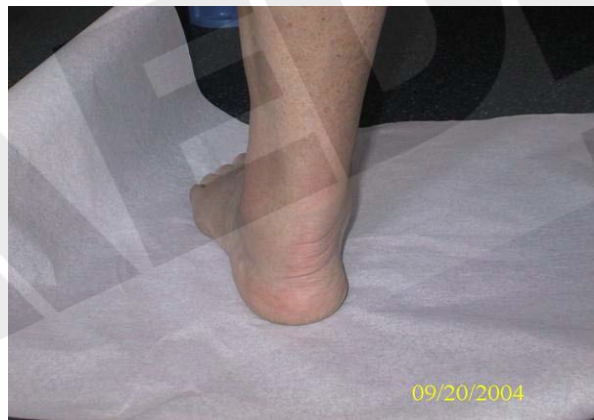
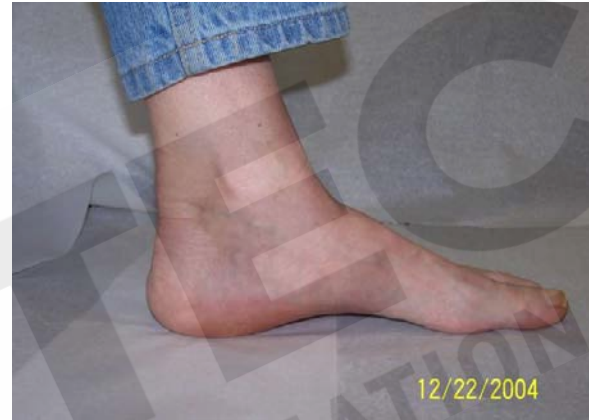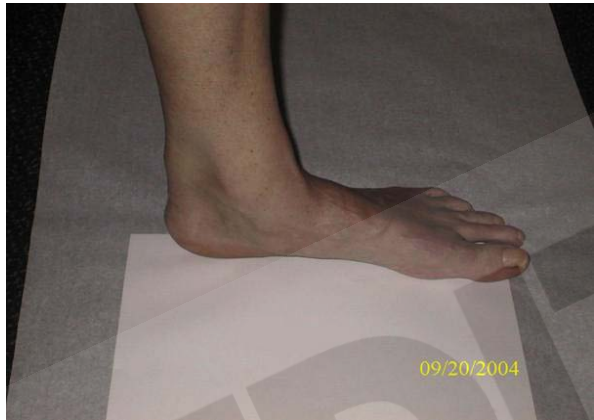# CASE #9

Patient#: XXXX

Age: 64 F

Diagnosis: Partial Tear of Left Achilles Tendon



Initial

After 10 Treatments

Tenderness, edema,  
partial loss of plantar flexion

100% function,  
asymptomatic